

Cases of Elder Abuse Are Difficult to Prove Without Forensic Research

**Please note that, out of respect for the victims, several images have been removed from this slide presentation in order to limit their circulation.*

To see the presentation with the images included, please view the full recording of the Webinar, “Elder Abuse Series: Forensic Markers” available on the Government Innovators Network website.

Role of Law Enforcement

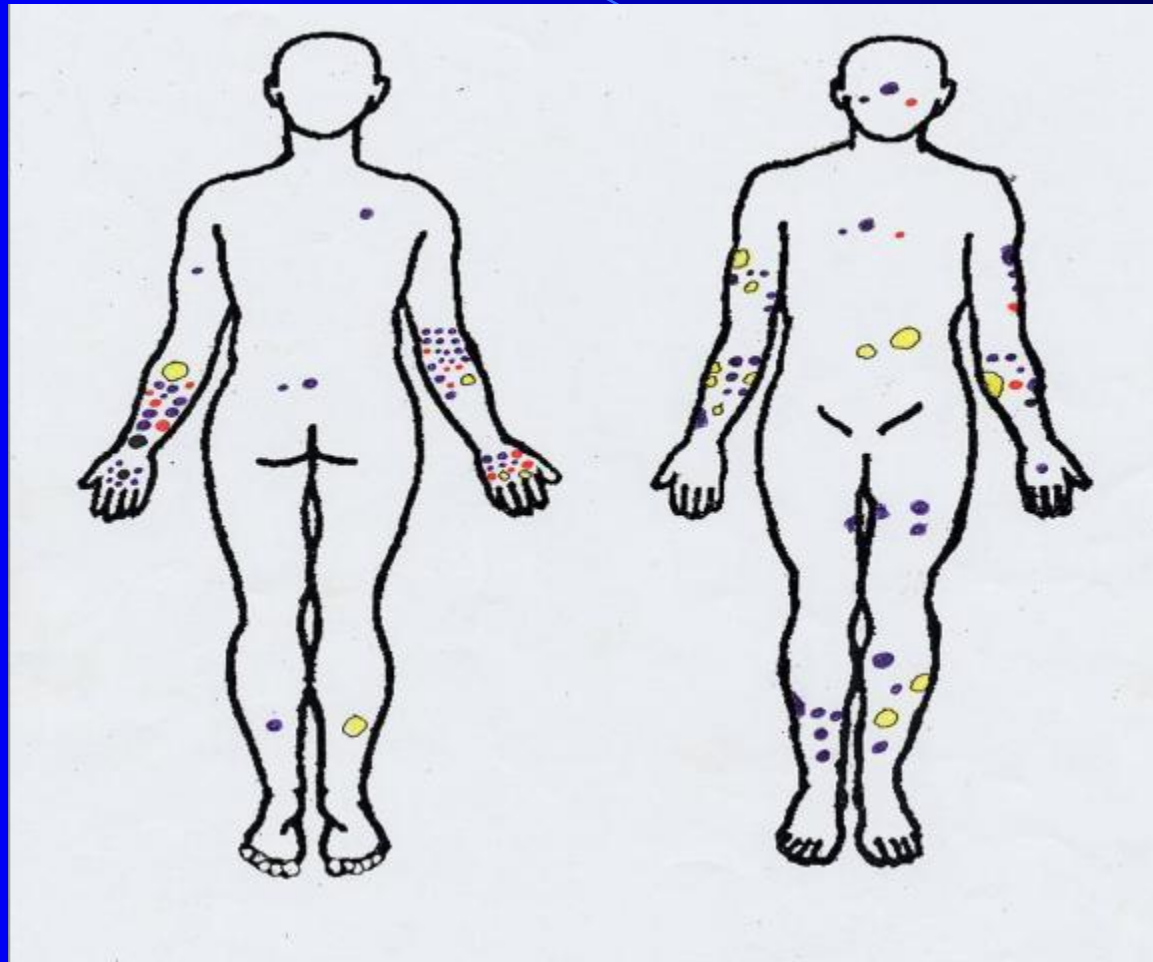
- Investigate cases of elder or dependent adult abuse with, or without, the testimony of the victim
- Gather evidence to prove each element of the crime
- Present the case to the District Attorney or City Attorney for criminal filing

Elder/Dependent Adult Abuse 368(a) PC

Crimes against elders and dependent adults are deserving of special protection *not* unlike the special protections provided for minor children. Elders and dependent adults may be:

- confused, on various medications, mentally or physically impaired, or incompetent
- less able to protect themselves
- less able to report criminal conduct
- less able to testify in court proceedings on their own behalf

PART I: Accidental Bruising in Older Adults



Citation: Mosqueda L, Burnight K, Liao S. The life cycle of bruises in older adults. J Am Geriatr Soc. 2005 Aug;53(8):1339-43.

This project was funded by Grant 2001-IJ-CX-KO14 from the Department of Justice (DOJ), Office of Justice Programs

- Color of a bruise did not indicate its age
- 90% of accidental bruises were on the extremities
- Less than a quarter of older adults with accidental bruises remembered how they received them

(JAGS 53:1339-1343, 2005)

Signs of Abuse

- bruises:
face, neck, torso, groin,
thighs, soles of feet
(JAGS 53:1339-1343, 2005)
- lacerations
- bedsores
- fractures
- rashes
- evidence of old and new
injuries

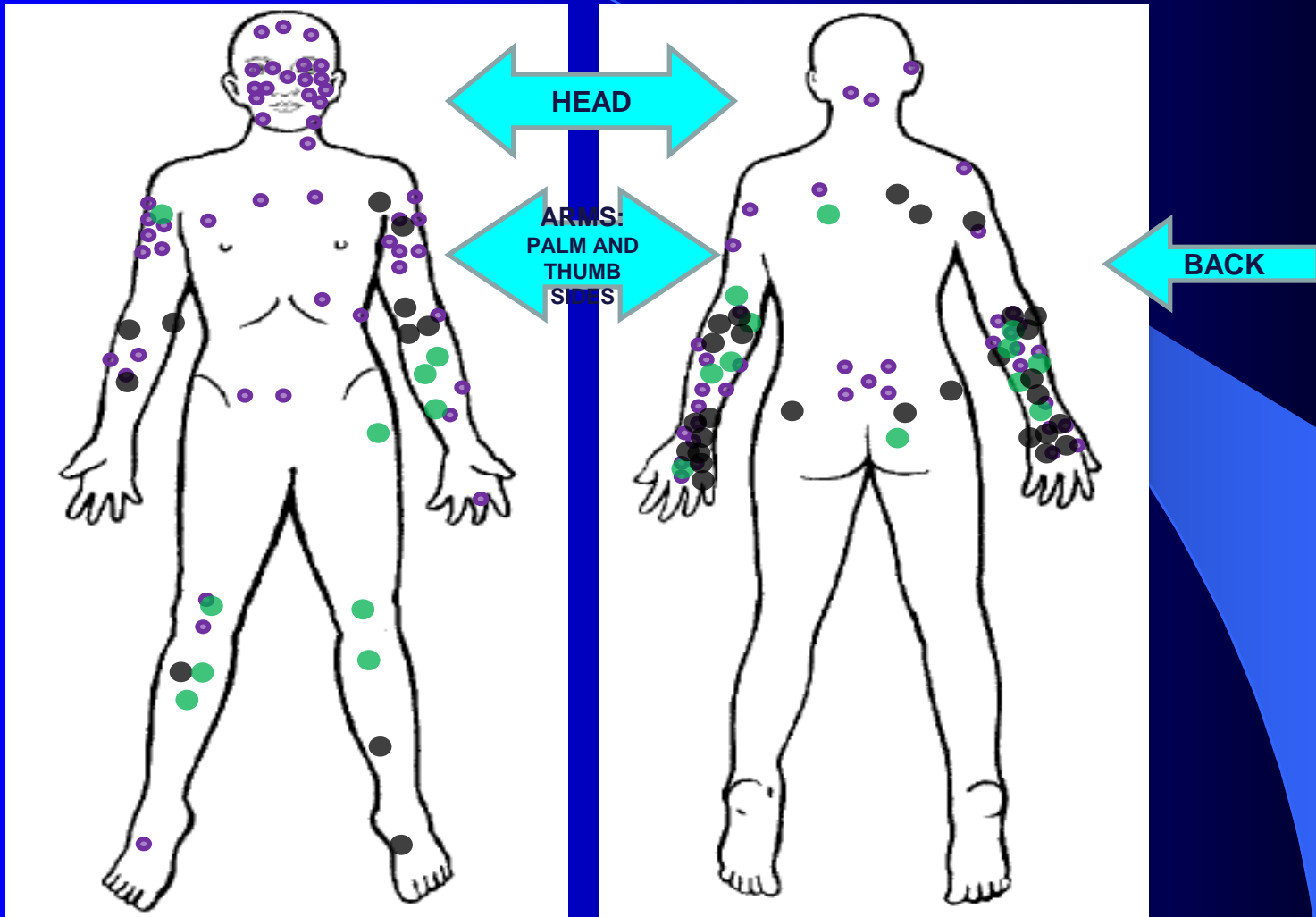
** Images removed*

“My Mom didn’t like me touching her.”

- 84 year old dies at home
- Her son is her caretaker
- She has unexplained bruising on her right breast and suspicious bruising on her right arm

** Images removed*

PART II: Bruising in Older Adults as Reported by Abused Elders



Bruising as a Marker of Physical Elder Abuse. J Am Geriatric Soc. 2009 Jul;57(7):1191-6.

This project was funded by Grant 2005-IJ-CX-0048 from the Department of Justice (DOJ), Office of Justice Programs

Unknown $f=39$
Accidental $f=23$
Inflicted $f=93$

“Football or Wrestling?”

- 74 year old with dementia
- 23 year old grandson residing in same home
- altercation over remote control
- bruising and laceration to wrist and face
- “Cereal box fell on my arm.”

** Images removed*

Memory and Dementia

- 40% of people with dementia had mostly reliable emotional memories (more recent and more stressful events were easier to remember)

Aileen Wiglesworth, Ph.D.

Funded by National Institute of Justice

Significance for Law Enforcement and Prosecution

- Emotional events encode in a unique fashion
- Reliability as a witness

The Hooded Man

- 78 year old woman
- moderate dementia
- 4 am daily walks alone
- family called police to placate victim
- victim vague but persistent
- hooded man in field
- exam revealed oral bruising and anal tears

** Images removed*

“She’s able to take care of herself.”

- 74 year old released from a skilled nursing facility three days prior.
- Left on the living room floor by her daughter who “assumed her mother had fallen off her sofa chair and crawled toward the front door”.
- Her daughter went to sleep. She heard her mother cry for help throughout the night and yelled at her to “lower her voice”.
- The victim was left to lie in her urine and fecal matter for 18 hours.
- She developed three Stage II bedsores and kidney failure.

** Images removed*

The Case of a Bedsore

Dr. Lisa Gibbs, geriatrician at UCI Medical Center, stated, "... conditions which put elders at risk for developing pressure sores include inability to move, lying on a hard surface, malnutrition, dehydration and a moist environment, such as urine."

The daughter was convicted of felony elder abuse.